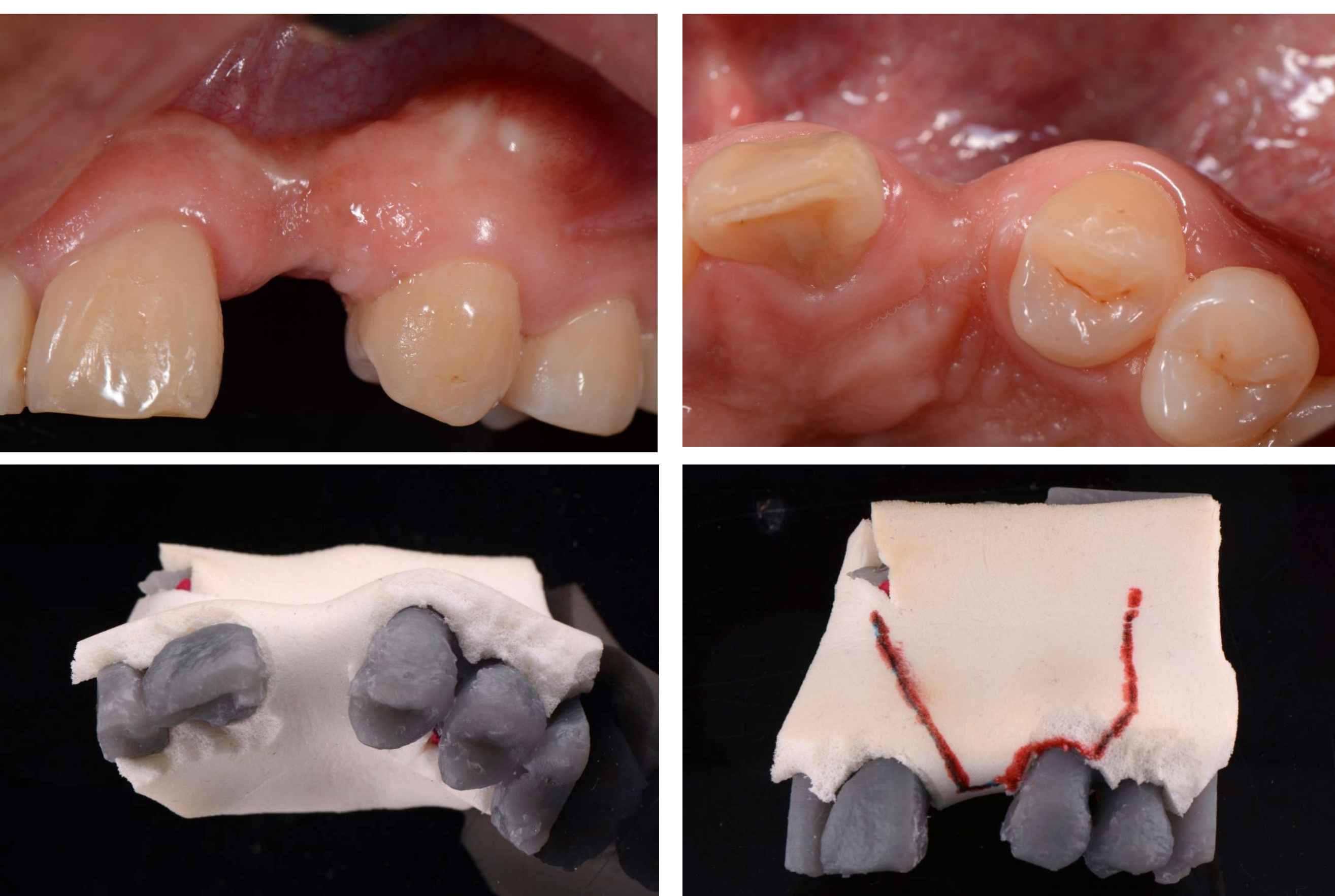


## ABSTRACT

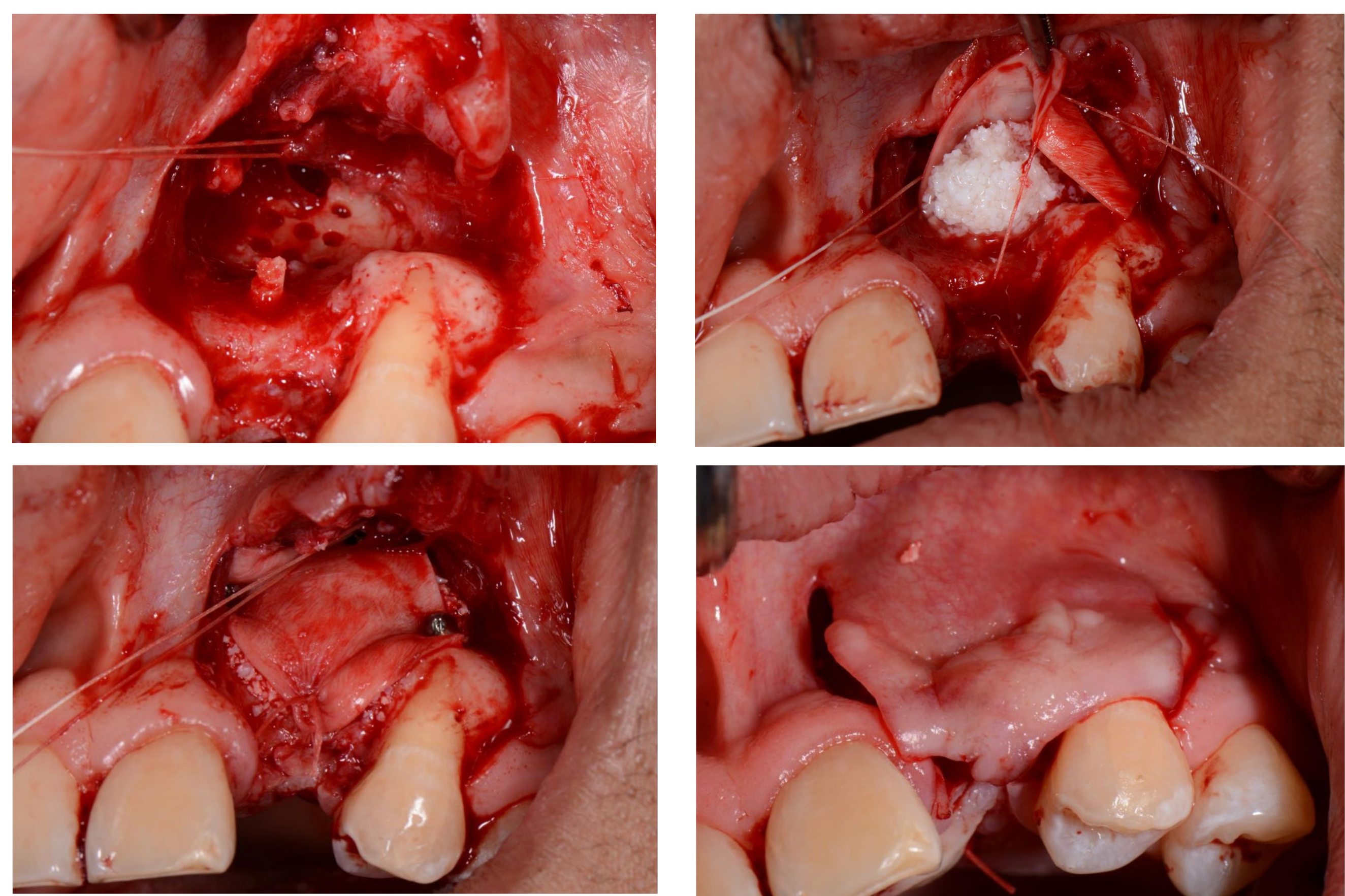
In order to create optimal esthetic and functional results for the placement of dental implants, there has been a focus towards bone augmentation procedures within patients with atrophic alveolar ridges. The most common and documented procedure for local bone augmentation is known as Guided Bone Regeneration, which uses the application of bone grafting material withheld by a non-resorbable membrane in the defective site of interest. Guided bone Regeneration yields effective results with a 95% success rate in terms of bone augmentation. A common complication after implant placement with GBR, however, is a facial concavity of the peri-

implant tissues, particularly when the facial bone or the overlying soft tissue is thin prior to or following tooth extraction. This observed defect requires ulterior intervention applying surgical techniques that improve the soft tissue contour of the implant site to avoid complications such as unesthetic results, food impaction and soft tissue irritation. The aim of this case report is to present the step-by-step diagnostic and clinical procedures followed to manage a buccal soft tissue depression at the implant site after guided bone regeneration, using xenograft particulate to obtain optimal soft tissue contour.

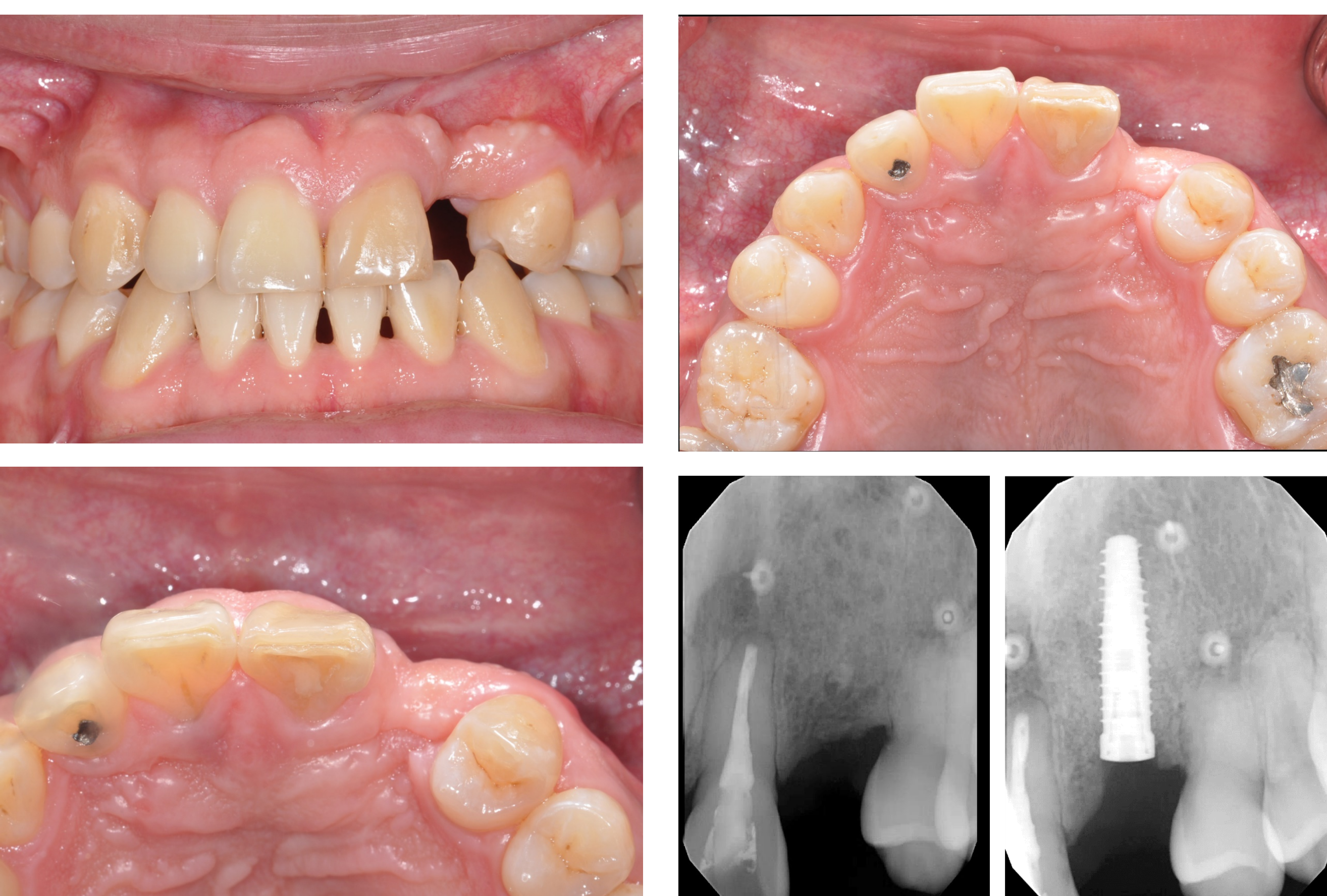
### STAGE 1: PRE-OP



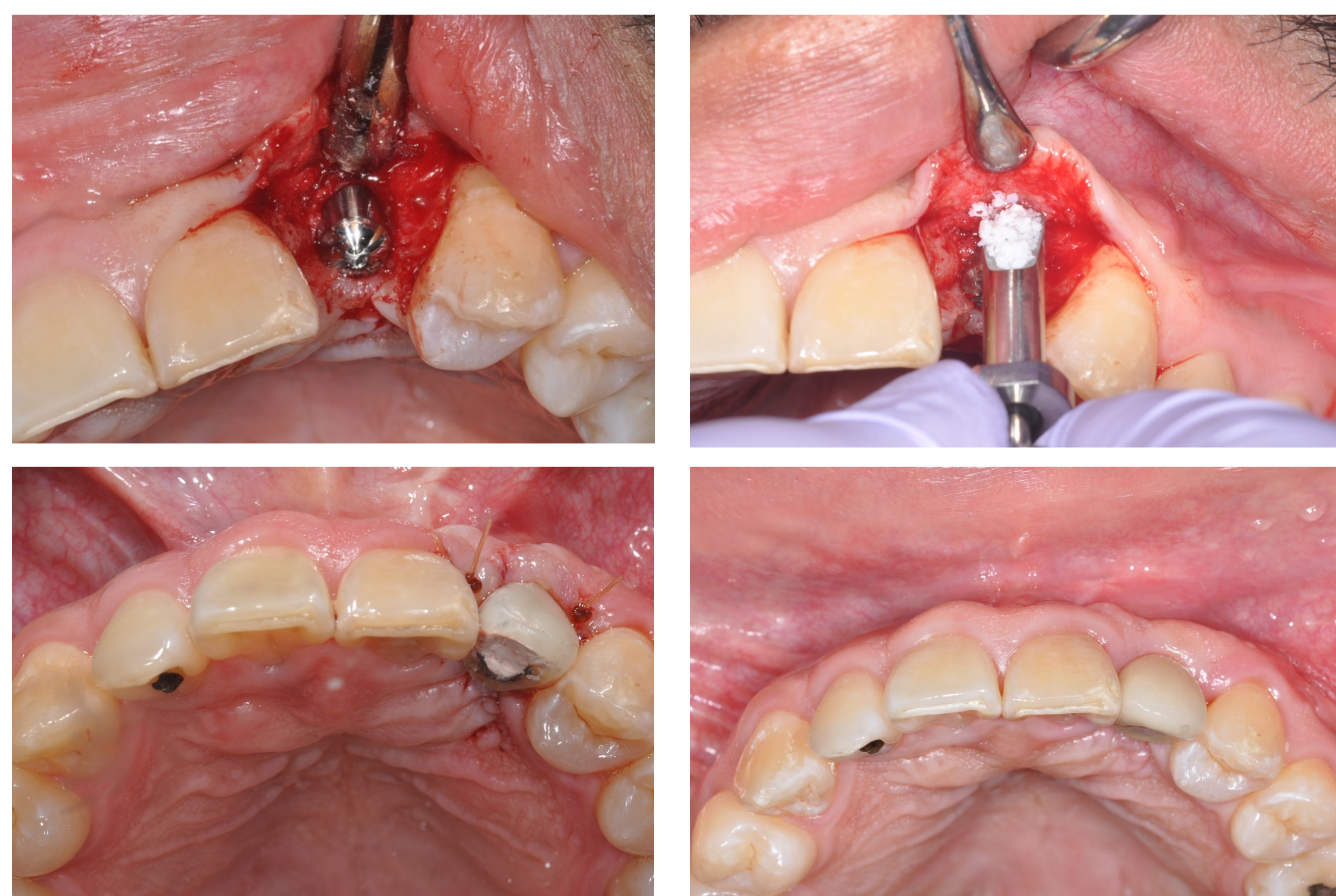
### STAGE 2: GBR



### STAGE 3: 2 MONTHS POST IMPLANT PLACEMENT



### STAGE 4: XEONGRAFT FILL AT SECOND STAGE



### CONCLUSION

Achieving ideal esthetic buccal contour of the soft tissues surrounding implant placement has been a prevalent problem and one that has been addressed by a multitude of different surgical and prosthetic procedures. The current study demonstrated a successful outcome using the xenograft fill technique in a patient with high esthetic demands in a site that has provided inadequate soft tissue contour. The step-by step surgical treatment showed an alternative way for recreating soft tissue while minimizing the post-operative risks and complications of other surgical techniques. Nevertheless, more studies including randomized controlled trials are necessary to confirm the result of the current case series.

### REFERENCES

1. Araújo, M. G., & Lindhe, J. (2005). Dimensional ridge alterations following tooth extraction. An experimental study in the dog. *Journal of clinical periodontology*, 32(2), 212–218.
2. Van der Weijden, F., Dell'Acqua, F., & Slot, D. E. (2009). Alveolar bone dimensional changes of post-extraction sockets in humans: a systematic review. *Journal of Clinical Periodontology*, 36(12), 1048–1058.
3. Khojasteh, A., Kheiri, L., Motamedian, S. R., & Khoshkam, V. (2017). Guided Bone Regeneration for the Reconstruction of Alveolar Bone Defects. *Annals of maxillofacial surgery*, 7(2), 263–277.
4. Chappuis, V., Rahman, L., Buser, R., Janner, S., Belser, U. C., & Buser, D. (2018). Effectiveness of Contour Augmentation with Guided Bone Regeneration: 10-Year Results. *Journal of dental research*, 97(3), 266–274.
5. Kois J. C. (2001). Predictable single tooth peri-implant esthetics: five diagnostic keys. *Compendium of continuing education in dentistry (Jamesburg, N.J. : 1995)*, 22(3), 199–208.
6. Benic, G. I., & Hämmerle, C. H. (2014). Horizontal bone augmentation by means of guided bone regeneration. *Periodontology 2000*, 66(1), 13–40.